



# Antiplatelets and antithrombotics in neurointerventional procedures: Guideline update

Clemens M Schirmer <sup>1</sup>, Ketan R Bulsara,<sup>2</sup> Fawaz Al-Mufti,<sup>3</sup> Neil Haranhalli,<sup>4</sup> Lucie Thibault,<sup>5</sup> Steven W Hetts <sup>6</sup>, SNIS Standards and Guidelines Committee

<sup>1</sup>Neurosurgery, Geisinger Health System, Wilkes-Barre, Pennsylvania, USA

<sup>2</sup>Division of Neurosurgery, University of Connecticut, Farmington, Connecticut, USA

<sup>3</sup>Neurology, Neurosurgery, and Radiology, Westchester Medical Center, Valhalla, New York, USA

<sup>4</sup>Neurosurgery and Radiology, Montefiore Hospital and Medical Center, Bronx, New York, USA

<sup>5</sup>Scientific Committee, World Federation of Interventional and Therapeutic Neuroradiology, Paris, France

<sup>6</sup>Radiology, Biomedical Imaging, and Neurological Surgery, UCSF, San Francisco, California, USA

## Correspondence to

Dr Steven W Hetts, Radiology, UCSF, San Francisco, CA 94143, USA; [steven.hetts@ucsf.edu](mailto:steven.hetts@ucsf.edu)

Received 4 November 2022

Accepted 22 April 2023

## ABSTRACT

**Background** Antiplatelet and antithrombotic medication management before, during, and after neurointerventional procedures has significant practice variation. This document updates and builds upon the 2014 Society of NeuroInterventional Surgery (SNIS) Guideline 'Platelet function inhibitor and platelet function testing in neurointerventional procedures', providing updates based on the treatment of specific pathologies and for patients with specific comorbidities.

**Methods** We performed a structured literature review of studies that have become available since the 2014 SNIS Guideline. We graded the quality of the evidence. Recommendations were arrived at through a consensus conference of the authors, then with additional input from the full SNIS Standards and Guidelines Committee and the SNIS Board of Directors.

**Results** The management of antiplatelet and antithrombotic agents before, during, and after endovascular neurointerventional procedures continues to evolve. The following recommendations were agreed on. (1) It is reasonable to resume anticoagulation after a neurointerventional procedure or major bleeding episode as soon as the thrombotic risk exceeds the bleeding risk in an individual patient (Class I, Level C-EO). (2) Platelet testing can be useful to guide local practice, and specific approaches to using the numbers demonstrate marked local variability (Class IIa, Level B-NR). (3) For patients without comorbidities undergoing brain aneurysm treatment, there are no additional considerations for medication choice beyond the thrombotic risks of the catheterization procedure and aneurysm treatment devices (Class IIa, Level B-NR). (4) For patients undergoing neurointerventional brain aneurysm treatment who have had cardiac stents placed within the last 6–12 months, dual antiplatelet therapy (DAPT) is recommended (Class I, Level B-NR). (5) For patients being evaluated for neurointerventional brain aneurysm treatment who had venous thrombosis more than 3 months prior, discontinuation of oral anticoagulation (OAC) or vitamin K antagonists should be considered as weighed against the risk of delaying aneurysm treatment. For venous thrombosis less than 3 months in the past, delay of the neurointerventional procedure should be considered. If this is not possible, see atrial fibrillation recommendations (Class IIb, Level C-LD). (6) For patients with atrial fibrillation receiving OAC and in need of a neurointerventional procedure, the duration of TAT (triple antiplatelet/anticoagulation therapy=OAC plus DAPT) should be kept as short as possible or avoided in favor of OAC plus single antiplatelet therapy (SAPT) based on the individual's ischemic and bleeding risk profile (Class IIa, Level B-NR). (7) For patients with unruptured brain arteriovenous malformations there is no indication

to change antiplatelet or anticoagulant management instituted for management of another disease (Class IIb, Level C-LD). (8) Patients with symptomatic intracranial atherosclerotic disease (ICAD) should continue DAPT following neurointerventional treatment for secondary stroke prevention (Class IIa, Level B-NR). (9) Following neurointerventional treatment for ICAD, DAPT should be continued for at least 3 months. In the absence of new stroke or transient ischemic attack symptoms, reversion to SAPT can be considered based on an individual patient's risk of hemorrhage versus ischemia (Class IIb, Level C-LD). (10) Patients undergoing carotid artery stenting (CAS) should receive DAPT before and for at least 3 months following their procedure (Class IIa, Level B-R). (11) In patients undergoing CAS during emergent large vessel occlusion ischemic stroke treatment, it may be reasonable to administer a loading dose of intravenous or oral glycoprotein IIb/IIIa or P2Y<sub>12</sub> inhibitor followed by maintenance intravenous infusion or oral dosing to prevent stent thrombosis whether or not the patient has received thrombolytic therapy (Class IIb, C-LD). (12) For patients with cerebral venous sinus thrombosis, anticoagulation with heparin is front-line therapy; endovascular therapy may be considered particularly in cases of clinical deterioration despite medical therapy (Class IIa, Level B-R).

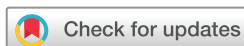**Conclusions** Although the quality of evidence is lower than for coronary interventions due to a lower number of patients and procedures, neurointerventional antiplatelet and antithrombotic management shares several themes. Prospective and randomized studies are needed to strengthen the data supporting these recommendations.

## BACKGROUND

This document updates and builds upon the 2014 Society of NeuroInterventional Surgery guideline 'Platelet function inhibitor and platelet function testing in neurointerventional procedures' (2014 SNIS Guideline).<sup>1</sup> Whereas the 2014 SNIS Guideline focused on a description of different agents and testing for their effects on platelet activity, the current document emphasizes pathology-specific considerations after a brief discussion of newly-approved reversal agents used for direct thrombin inhibitors and clotting factor Xa inhibitors, and an update on platelet function testing.

## METHODS

We performed a structured literature review of studies that have become available since the 2014 SNIS Guideline using methods similar to that document. Recommendations were developed based on the existing literature that has become



© Author(s) (or their employer(s)) 2023. No commercial re-use. See rights and permissions. Published by BMJ.

**To cite:** Schirmer CM, Bulsara KR, Al-Mufti F, et al. *J NeuroIntervent Surg* Epub ahead of print: [please include Day Month Year]. doi:10.1136/jnis-2022-019844

available since 2014, a robust discussion regarding the interpretation of the literature, and the collective experience of the members of the writing group. Experts from academic institutions in North America from the specialties of neurosurgery, neurology, interventional neuroradiology, and pharmacology were recruited based on their expertise. A computerized search of the MEDLINE database (PubMed) from December 1, 2013 to September 30, 2022 was performed using search terms including ‘antiplatelet’, ‘anticoagulant’, ‘treatment’, ‘endovascular’, ‘neuro-endovascular’, and ‘interventional radiology’ to identify published articles on the use of antiplatelet and anticoagulant medications in the management of patients undergoing neurointerventional procedures. Relevant English language articles were taken into consideration while writing this consensus paper. The literature review consisted mostly of case series and non-randomized single-center studies. We graded the quality of the evidence. Recommendations were arrived at through a consensus conference of the authors, then with additional input from the full SNIS Standards and Guidelines Committee and the SNIS Board of Directors.

## REVERSAL OF DIRECT ORAL ANTICOAGULANTS

Since publication of the 2014 SNIS Guideline, direct oral anticoagulants (DOACs)—including the direct thrombin inhibitor dabigatran and the direct factor Xa inhibitors apixaban, betrixaban, edoxaban, and rivaroxaban—have increased significantly.<sup>2</sup> This class of anticoagulants is now the most widely prescribed oral anticoagulation (OAC) in the world.<sup>3–5</sup> As it is increasingly likely that neurointerventionalists will encounter patients on DOACs and that these agents might lead to increased hemorrhagic risks for some neurointerventional procedures, it is now helpful to understand how these agents can be reversed in urgent and emergent settings. From a practical standpoint, reversal of these agents can be broken into two categories.

### Direct thrombin inhibitor reversal

For direct thrombin inhibitor (dabigatran) reversal, idarucizumab is a humanized, monoclonal, anti-dabigatran antibody fragment that has shown good efficacy since its approval by the US Food and Drug Administration (FDA) in 2015.<sup>2</sup> The REVERSE-AD study revealed median time to hemostasis of 2.5 hours.<sup>6</sup> About 25% of patients had re-elevation in plasma dabigatran 24 hours after the initial treatment; however, they responded well to re-treatment. The thrombotic rate in the study cohort was 4.8% at 1 month. Another option for reversal of direct thrombin inhibitors is activated prothrombin complex concentrate (APCC), a plasma derived concentrate of vitamin K-dependent clotting factors which are partially activated by

**Table 2** Reversal agents for anticoagulants

Anticoagulant	Reversal agent
Heparin	Protamine sulfate
LMWH	Protamine sulfate (partial reversal)
Warfarin	Vitamin K
Dabigatran	Idarucizumab
Apixaban	Andexanet alfa
Edoxaban	Andexanet alfa
Rivaroxaban (higher doses)	Andexanet alfa
No data show that fast reversal of a direct oral anticoagulant leads to a better clinical outcome. <sup>96</sup>	
LMWH, low molecular weight heparin.	

proteolytic cleavage and hemodialysis. Based on guidance from the anticoagulation forum, if reversal of dabigatran is necessary, idarucizumab 5 g IV is recommended.<sup>2</sup> If not available, APCC (50 units/kg IV) is recommended.

### Direct factor Xa inhibitor reversal

Andexanet alfa was approved for direct factor Xa inhibitor reversal by the FDA in 2018. It is a modified recombinant inactive factor Xa that has the ability to bind and sequester factor Xa inhibitors.<sup>2</sup> Alternatively, prothrombin complex concentrates (PCCs) are inactive forms of vitamin K-dependent clotting factors plasma derived concentrates. Approximately 58% effective hemostasis was noted with PCCs.<sup>2</sup>

Based on guidance from the anticoagulation forum, if reversal of direct factor Xa inhibitors rivaroxaban or apixaban is needed, andexanet alfa can be administered as an initial bolus (either 400 mg or 800 mg IV at rate 30 mg/min followed by infusion (either 4 mg/min or 8 mg/min) for up to 120 min. The dose given is dependent on the patient dose of the direct factor Xa inhibitor and time from last taking the medication. If andexanet alfa is not available, four-factor PCC 2000 units is recommended. For reversal of edoxaban and betrixaban, off label use of andexanet alfa (800 mg bolus followed by a continuous infusion of 8 mg/min for up to 120 min) or four-factor PCC 2000 units is recommended.<sup>2</sup>

A recent consensus paper among the community treating coronary artery disease recommends resumption of anticoagulation after major bleeding as soon as the individual patient's thrombotic risk exceeds the rebleeding risk. In many cases, this resumption can be within 1 week in that population.<sup>7</sup> Although data are less clear in the neurointerventional community, it may be reasonable to apply similar timing to neurovascular patients

**Table 1** How to switch between different anticoagulants

Switching between agents	How to switch	Comments
VKA to NOAC	Once the INR is <2	When transitioning from oral VKA to new direct oral anticoagulants (NOACs) in patients who cannot achieve consistent INR
IV UFH to NOAC	2 hours after stopping UFH	When going from IV to oral
LMWH to NOAC	When the next dose of LMWH was due	When transitioning from LMWH to new direct oral anticoagulant (NOACs)
NOAC to VKA	Concomitant treatment until INR=2 to 3	If patient cannot tolerate NOAC or does not have access to it
NOAC to UFH or LMWH	When the next dose of NOAC was due	When going from new direct oral anticoagulant (NOACs) to parenteral administration
One NOAC to another NOAC	When the next dose of first NOAC was due	When switching between one NOAC to another NOAC
INR, international normalized ratio; <sup>95</sup> IV, intravenous; LMWH, low molecular weight heparin; NOAC, novel oral anticoagulant; UFH, unfractionated heparin; VKA, vitamin K antagonist.		

as to coronary artery disease patients. [Table 1](#) (How to switch between different anticoagulants) and [table 2](#) (Reversal agents for anticoagulants) are provided for readers' reference.

**Recommendation 1: It is reasonable to resume anticoagulation after a neurointerventional procedure or major bleeding episode as soon as the thrombotic risk exceeds the bleeding risk in an individual patient (Class I, Level C-EO)**

**Testing platelet response**

The use of antiplatelet medication response testing before neuroendovascular procedures remains heterogeneous in the neurointerventional community.<sup>8–10</sup> Although a randomized trial for elective unruptured brain aneurysm coil embolization demonstrated reduced thromboembolic complications when antiplatelet medication approaches were modified based on aspirin reactive units (ARU) >550 or platelet reactive units (PRU) >213, use of such thresholds has not been widely adopted.<sup>11</sup> In order to reduce thromboembolic complications associated with placement of neurovascular stents, use of dual antiplatelet therapy (DAPT) has become routine practice in the last decade.<sup>12–15</sup> Although most protocols are derived from the cardiac literature, there is marked heterogeneity in the platelet response to clopidogrel of patients undergoing neurointerventional procedures.<sup>16</sup> Standard daily oral doses of clopidogrel fail to completely inhibit adenosine diphosphate (ADP)-induced platelet aggregation in up to 30% of patients, a phenomenon labeled 'poor response'.<sup>17</sup> There is emerging evidence supporting the use of either platelet function testing via the FDA-approved VerifyNow P2Y12 assay or genetic testing for CYP2C19 loss-of-function allele status to ensure an appropriate level of reduction in platelet activation and aggregation to reduce adverse outcomes.<sup>18</sup> There is good evidence that loss-of-function polymorphisms are associated with reduced levels of the active clopidogrel metabolite and with reduced on-treatment inhibition of ADP-induced platelet activation.<sup>19</sup> Loss of function genotypes for these alleles do not alter the pharmacodynamics of other P2Y12 inhibitors such as prasugrel or ticagrelor. There is an increasing body of evidence that suggests that the PRU as assessed by the VerifyNow P2Y12 assay—though sometimes limited by low platelet count or low hematocrit—is the most useful assay at predicting periprocedural hemorrhagic and thrombotic complications during FD placement, although thromboelastography may also be useful in predicting CNS ischemic and access site hemorrhagic complications.<sup>20–23</sup>

A neurointerventional study of 96 patients undergoing neurovascular stenting (including carotid stents, intracranial stents for atherosclerosis and stent-assisted aneurysm coiling, and a vertebral artery stent for atherosclerosis) demonstrated a 16% risk of thromboembolism in clopidogrel-resistant patients compared with 1.6% in non-resistant patients ( $P < 0.01$ ).<sup>24</sup> Another study of 44 patients undergoing aneurysm flow diversion embolization with Pipeline endovascular devices (PEDs), a pre-procedure PRU value of >240 predicted perioperative thromboembolic complications.<sup>25</sup> Unlike coronary interventions—in which only an upper bound for PRU typically alters treatment plans because coronary thrombosis is the primary concern—cerebral arterial intervention plans may be altered if the PRU is <40 (increased hemorrhage risk) or >240 (increased thrombosis risk), though no consensus on exact numbers exists. PREMIER was the first prospective multicenter study to evaluate the use of flow diverters (FDs) in 141 patients with small/medium, unruptured intracranial aneurysms (IAs) located in the internal carotid artery and vertebral artery. Patients were tested for antiplatelet drug

response using VerifyNow before FD implantation. PRU were required to be between 60 and 200. Patients with a PRU value outside this range were excluded. At 1 year follow-up post FD implantation, there were 140 patients with available data, three (2.1%) experienced a primary safety endpoint event (major stroke), with one leading to neurological death. There were no cases of intraoperative aneurysm rupture, delayed aneurysm rupture, or documented recurrence after complete aneurysm occlusion.<sup>26</sup> The authors commented that limiting the use of FDs to patients responsive to antiplatelet therapy seems to yield better results.

While neurointerventional studies are limited, it may also be appropriate to extrapolate from the stroke literature.<sup>27</sup> The CHANCE 2 trial was a randomized, double-blind, placebo-controlled trial involving 6412 patients with a minor ischemic stroke or transient ischemic attack (TIA) who carried CYP2C19 loss-of-function alleles, and were assigned to receive ticagrelor or clopidogrel; the risk of stroke at 90 days was lower with ticagrelor than with clopidogrel, with no increased risk of severe or moderate bleeding.<sup>28</sup> In a subgroup analysis of CHANCE 2 examining the association between CYP2C19 loss-of-function allele status and efficacy of clopidogrel for risk reduction among patients with minor stroke or transient ischemic attack, the use of clopidogrel plus aspirin compared with aspirin alone reduced the risk of a new stroke only in patients who were not carriers of the CYP2C19 loss-of-function alleles.<sup>29</sup> CYP2C19 loss-of-function polymorphisms are present in 25% of Caucasian patients and 60% of Asian patients who have reduced ability to convert clopidogrel to its active form. These findings support a role for CYP2C19 genotype in the efficacy of antiplatelet treatment.

**Recommendation 2: Platelet testing can be useful to guide local practice, and specific approaches to using the numbers demonstrate marked local variability (Class IIa, Level B-NR)**

'Black box' warnings for antiplatelet and anticoagulant medications As the field gains more experience with newer generations of antiplatelet and anticoagulant medications, it is important to remain updated with labeling changes. The FDA issues labeling cautions in one of three situations: (1) as a precaution when special situations or patient groups have to be taken into account; (2) as a warning where there is a potential safety hazard of a serious adverse event, a 'boxed warning' or 'black box warning' (BBW) is the strongest warning the FDA can issue ([table 3](#)); and (3) as a contraindication when there is a situation where the risk is considered greater than the possible benefit.<sup>30</sup> A BBW is used when there is an adverse reaction so serious that a change in management is indicated. Medical comorbidities, including but not limited to deep venous thrombosis, atrial fibrillation, and other cardiac considerations—for example, the need for or recent coronary interventions or idiopathic pathologically low platelet levels—introduce constraints on the customary employment of DAPT for elective aneurysm interventions. Risk to benefit of any given drug is an essential consideration. A serious adverse reaction can be prevented or reduced in frequency or severity by appropriate use of the drug (for example, patient selection, monitoring, avoiding interactions, and considering comorbidities).

**DISEASE-SPECIFIC CONSIDERATIONS**

**Brain aneurysm treatment**

Antiplatelet therapy in combination with oral anticoagulant therapy is common in real-world clinical practice, with

**Table 3** 'Black box warning' (BBW) labels for selected antiplatelet agents

Drug	FDA initial approval	Date of BBW	Warning
Clopidogrel (Plavix)	November 17, 1997	March 12, 2010	The effectiveness of clopidogrel results from its antiplatelet activity, which is dependent on its conversion to an active metabolite by the cytochrome P450 (CYP-450) system, principally CYP2C19. Clopidogrel at recommended doses forms less of the active metabolite and has a reduced effect on platelet activity in patients who are homozygous for non-functional alleles of the CYP2C19 genes (termed 'CYP2C19 poor metabolizers'). Tests are available to identify patients who are CYP2C19 poor metabolizers. Consider use of another platelet P2Y <sub>12</sub> inhibitor in patients identified as CYP2C19 poor metabolizers
Dipyridamole/ASA (Aggrenox)	November 22, 1999	N/A	—
Eptifibatide (Integrilin)	June 8, 2001	N/A	—
Prasugrel (Effient)	July 10, 2009	July 10, 2009	Prasugrel can cause significant and sometimes fatal bleeding. Do not use prasugrel in patients with active pathological bleeding or a history of transient ischemic attack or stroke. Risk factors for bleeding include bodyweight <60 kg, propensity to bleed, and concomitant use of medications that increase the risk of bleeding (eg, warfarin, heparin, fibrinolytic, chronic use of NSAIDs). Prasugrel is not recommended in patients 75 years of age or older, except for high-risk situations (diabetes, history of prior myocardial infarction). Do not start prasugrel in patients likely to undergo urgent CABG and discontinue at least 7 days before any surgery. If possible, manage bleeding without discontinuing prasugrel, as discontinuation in the first few weeks after acute coronary syndrome may increase risk for subsequent cardiovascular events
Ticagrelor (Brilinta)	July 20, 2011	July 20, 2011	Ticagrelor can cause significant, sometimes fatal, bleeding. Do not use in patients with active pathological bleeding or history of intracranial hemorrhage. Do not start in patients undergoing urgent CABG. If possible, manage bleeding without discontinuing ticagrelor. Stopping ticagrelor increases the risk of subsequent cardiovascular events. Maintenance doses of aspirin above 100 mg in patients with acute coronary syndrome reduce the effectiveness of ticagrelor and should be avoided

Reference: <https://www.fda.gov/drugs/drug-safety-and-availability/drug-safety-communications> Accessed November 1, 2022.<sup>97</sup>

ASA, aspirin; CABG, coronary artery bypass grafting; FDA, US Food and Drug Administration; NSAIDs, non-steroidal anti-inflammatory drugs.

overlapping use as high as 39–55% in some patient groups.<sup>31</sup> The evidence for this practice is less clear, and a smaller number of patients meet criteria for combination therapy, as many patients may be continued on long-term combination therapies that provide little additional benefit, and carry significant risk for harm.<sup>31</sup> The benefits of employing DAPT in patients undergoing neurointerventional procedures have been addressed in the 2014 SNIS Guideline.<sup>1</sup> Table 3 lists warning labels on selected antiplatelet medications; table 4 lists considerations for modifying antiplatelet or anticoagulant regimens for neurointerventional procedures based on patients' comorbid conditions. It is helpful to distinguish scenarios ranging from emergent procedures for ruptured aneurysms to elective procedures for unruptured aneurysms.

### Ruptured aneurysm treatment

The pharmacologic management with antiplatelet or antithrombotic agents accompanying the endovascular management of a ruptured aneurysm is heterogeneous and few high quality data points to guide management exist. Some authors have suggested that management of ruptured aneurysms can be similar to unruptured aneurysms, after placement of a ventriculostomy as needed to manage the subarachnoid hemorrhage. The preferred periprocedural approach consisted of a dual antiplatelet regimen including aspirin plus an intravenous glycoprotein IIb/IIIa inhibitor with subsequent conversion to oral medications after the procedure.<sup>32</sup> A systematic review of stent-assisted coiling of ruptured brain aneurysms found that, compared with the

**Table 4** Antiplatelet and anticoagulation management for selected neurointerventional treatment procedures

	Unruptured aneurysm*	Ruptured aneurysm†	Unruptured AVM‡	Ruptured AVM§	ICAD¶	CAS**
No comorbidities	None, SAPT or DAPT††	None, SAPT, or DAPT	None or SAPT	None	DAPT	DAPT
Coronary stent/PCI	DAPT	SAPT if ≥3–6 months post PCI. DAPT if <3–6 months post PCI	DAPT	SAPT if ≥3–6 months post PCI. DAPT if <3–6 months post PCI	DAPT	DAPT
Atrial fibrillation	AC+SAPT or AC+DAPT, reassess risk at 3 months	SAPT, reassess risk at 1 month	AC+SAPT or AC+DAPT, reassess risk at 3 months	SAPT, reassess risk at 1 month	AC+SAPT or AC+DAPT, reassess risk at 3 months	AC+SAPT or AC+DAPT, reassess risk at 3 months
Acute systemic venous thrombosis	AC+SAPT or AC+DAPT, reassess risk at 3 months	SAPT, consider IVC filter, reassess risk at 1 month	AC+SAPT or AC+DAPT, reassess risk at 3 months	SAPT, consider IVC filter, reassess risk at 1 month	AC+SAPT or AC+DAPT, reassess risk at 3 months	AC+SAPT or AC+DAPT, reassess risk at 3 months

How to use this table: These recommendations are not exhaustive but instead are meant as a general approach. Medications need to be individualized to a particular patient using multidisciplinary management.

\*Unruptured aneurysm (or ruptured aneurysm ≥14 days after rupture)—including coiling (SAPT), balloon-assisted coiling (SAPT), stent-assisted coiling (DAPT), flow-diverting stent (DAPT), intrasaccular flow disruption (DAPT).

†Ruptured aneurysm (<14 days after rupture)—including coiling (none), balloon-assisted coiling (none), stent-assisted coiling (procedural IV DAPT converted to oral DAPT within 24 hours\*\*), flow-diverting stent (procedural IV DAPT converted to oral DAPT within 24 hours\*\*), intrasaccular flow disruption (none or SAPT\*\*). Note that open surgery may be preferable to endovascular therapy for aneurysms amenable to surgical therapy given the complexity of antiplatelet management in patients with ruptured aneurysms who may also need extraventricular drain placement.

‡Unruptured AVM—including transarterial or transvenous n-BCA, EVOH, or coil embolization.

§Ruptured AVM—including transarterial or transvenous n-BCA, EVOH, or coil embolization.

¶Intracranial atherosclerotic disease (ICAD)—including angioplasty and/or stenting.

\*\*Carotid artery stenting (CAS)—including angioplasty and stenting.

††See also 2014 SNIS Guideline

‡‡Ospel *et al*, 2020<sup>98</sup>

AC, anticoagulation; AVM, arteriovenous malformation; DAPT, dual antiplatelet therapy (usually aspirin plus another agent); EVOH, ethylene vinyl alcohol copolymer; IV, intravenous; IVC, inferior vena cava; n-BCA, n-butyl cyanoacrylate; PCI, percutaneous coronary intervention; SAPT, single antiplatelet therapy (usually aspirin monotherapy).



management of unruptured aneurysms, delayed post-procedural administration of the antiplatelet agent led to increased risk of thromboembolic events, different than an earlier pre-procedure and intra-procedure antiplatelet administration. The latter practice resulted in thromboembolic risk similar to stent coiling of unruptured aneurysms.<sup>33</sup> Another non-randomized retrospective study of stent-assisted coiling of ruptured brain aneurysms recently described the use of DAPT (aspirin and clopidogrel) loading immediately before the procedure, intravenous heparin during the procedure, intra-arterial tirofiban during the procedure if stent thrombosis was evident, and SAPT or DAPT following the procedure. They report similar event rates compared with a group of patients undergoing primary coiling alone, ranging from 1.4% for rebleeding and post-procedural cerebral infarction to 2.8% for intra-procedural thrombotic events.<sup>34</sup> Several reports from the literature suggest a reduction in thromboembolic events when utilizing clopidogrel.<sup>15 35–37</sup> Whether or not the addition of aspirin matters is less well understood, and many practitioners use aspirin instead of clopidogrel in the post-procedure setting.

### Unruptured aneurysm treatment

For unruptured aneurysm treatment, it is helpful to consider the scenarios of primary coil embolization, coiling with balloon assistance, stent-assisted coiling, intrasaccular flow disruptor placement, and parent artery flow diversion using braided stents. Based on increasing experience deploying FDs in the last decade, many practitioners have become accustomed to using DAPT guided by point of care testing for many of the above scenarios, except for primary coil embolization. A recent meta-analysis of 1005 patients undergoing intracranial flow diversion also concluded that dual antiplatelet regimens including ticagrelor or prasugrel are safe and that ticagrelor use may be associated with better survival than clopidogrel use.<sup>38</sup> There has been increasing interest in using point of care testing and the PRU metric to guide therapy, especially for FD placement, but there continues to be no prospectively validated recommendation for a therapeutic range.<sup>25 39</sup>

**Recommendation 3: For patients without comorbidities undergoing brain aneurysm treatment, there are no additional considerations for medication choice beyond the thrombotic risks of the catheterization procedure and aneurysm treatment devices (Class IIa, Level B-NR)**

**Recommendation 4: For patients undergoing neurointerventional brain aneurysm treatment who have had cardiac stents placed within the last 6–12 months, DAPT is recommended (Class I, Level B-NR)**

Comorbidities: venous thrombosis

Venous thromboembolism (VTE) may require long-term anticoagulation therapy. The initial active treatment phase is often 3 months, with prolonged treatment directed at secondary prevention. Thus, VTE should ideally be treated for either 3 months or indefinitely, but long-term risk of recurrence, risk of bleeding, and patient preference make this decision less clear.<sup>40</sup> Indefinite anticoagulation is sometimes recommended when a low risk of bleeding can be assumed. Conversely, a high risk of bleeding often results in stopping anticoagulation at 3 months.

Further factors supporting the decision to continue anticoagulation indefinitely are male gender, the index event pulmonary embolism rather than deep vein thrombosis (DVT), or a positive d-dimer test 1 month after stopping anticoagulant therapy.<sup>40 41</sup>

If a factor indicating higher bleeding risk changes in a particular patient, then a reassessment of the balance of risk and benefits would be indicated. The 2016 CHEST guidelines make recommendations about the use of aspirin alone; while not considered a reasonable alternative to anticoagulation for the extended prophylaxis of DVT, the authors concede that anticoagulation may have to be stopped for other reasons.<sup>42</sup>

**Recommendation 5: For patients being evaluated for neurointerventional brain aneurysm treatment who had venous thrombosis more than 3 months prior, discontinuation of OAC or vitamin K antagonist should be considered as weighed against the risk of delaying aneurysm treatment. For venous thrombosis less than 3 months in the past, delay of the neurointerventional procedure should be considered. If this is not possible, see atrial fibrillation recommendations (Class IIb, Level C-LD)**

Comorbidities: atrial fibrillation

Atrial fibrillation is commonly managed with anticoagulation to reduce embolic stroke risk. The employment of DAPT in addition to anticoagulation, also known as triple antithrombotic/anticoagulant therapy (TAT), however, has been associated with an increased risk of hemorrhagic complications compared with the use of either component alone.<sup>43–47</sup> From the cardiac literature, we can now glean data that compare TAT with alternative antithrombotic therapy regimens, such as double antithrombotic therapy (DAT), which combines OAC with single antiplatelet therapy (SAPT).<sup>43–47</sup>

Concerning non-valvular atrial fibrillation, a meta-analysis that included four randomized controlled trials of different non-vitamin K antagonist oral anticoagulants (NOACs) found that the combination of an antiplatelet agent and NOACs (dual therapy) is associated with a smaller risk of major bleeding and intracranial hemorrhage without significant difference in ischemic events (stroke, myocardial infarction or stent thrombosis).<sup>48</sup> Angiolillo and co-workers provide a focused updated of the 2018 recommendations of the North American consensus statements on the management of antithrombotic therapy in patients with atrial fibrillation undergoing percutaneous coronary intervention.<sup>49</sup> They recommend dual therapy using aspirin and a P2Y12 inhibitor for atrial fibrillation patients during the peri-percutaneous coronary intervention (PCI) period (during the inpatient stay, up to 1 week after PCI, or at the discretion of the treating physician).<sup>49</sup> Thereafter it is the default strategy to stop aspirin and continue a P2Y12 inhibitor, preferably clopidogrel, in combination with a NOAC (ie, double therapy). Note that this is different from the DAT recommendation above. In patients with increased thrombotic risk but acceptable risk of bleeding, it is recommended to continue aspirin (ie, TAT) for up to 1 month. DAT should be given for 6 to 12 months, calibrated to the specific risk profile for ischemic and hemorrhagic events of the patient. Later patients should discontinue antiplatelet therapy and receive OAC alone.

Patients with atrial fibrillation should receive OAC to prevent the risk of thromboembolic events, whereas antiplatelet therapy is required to prevent stent thrombosis in the setting of PCI.<sup>49</sup> In the coronary literature, several randomized trials have demonstrated that DAT combined with DOACs provide a preferable safety profile compared with a regimen of TAT with vitamin K antagonist. A course of TAT (the combination of OAC with DAPT) should be kept as short as possible or even avoided based on the individual's ischemic and bleeding risk profile.<sup>49</sup>

**Recommendation 6: For patients with atrial fibrillation receiving OAC and in need of a neurointerventional procedure, the duration of TAT (OAC plus DAPT) should be kept as short as possible or avoided in favor of OAC plus SAPT based on the individual's ischemic and bleeding risk profile (Class IIa, Level B-NR)**

Antiplatelet and anticoagulant use in patients with brain arteriovenous malformations and during embolization procedures. There is no consensus on the use of anticoagulation or antiplatelet medications during embolization of brain arteriovenous malformations (AVMs).<sup>50</sup> The SNIS Standards and Guidelines expert panel agreed that standard systemic heparinization used for common procedures like aneurysm coiling may be a reasonable approach to embolization for unruptured brain AVMs. Some interventionalists will choose to reverse heparin with protamine at the end of the case and others will allow heparin to wear off without reversal. For ruptured AVMs, it may be preferable to reverse anticoagulation at the end of the case. This can be confounded, however, by the effect of intracranial hemorrhage on electrocardiographic findings that can simulate myocardial infarction.<sup>51</sup>

For high-flow AVMs, particularly in the setting of AVM rupture, physicians may choose not to use routine intraprocedural systemic heparinization on the assumption that the high flow will mitigate against thrombus formation on endovascular catheters in feeding arteries. For unruptured pediatric high-flow arteriovenous fistulas, however, a case study has identified jugular venous outflow stenosis or occlusion as a risk factor for post-embolization cerebral venous thrombosis.<sup>52</sup> The authors of that study therefore advocate short-term post-procedural anticoagulation with low molecular weight heparin (LMWH) to prevent cerebral venous thrombosis. A similar rationale underlies the prescription of aspirin and heparin to prevent cerebral venous thrombosis following resection of >4cm brain AVMs with extensive venous outflow networks in a large single-center experience.<sup>53</sup> Underlying prothrombotic conditions such as factor V Leiden may predispose patients to have an AVM nidus and venous outflow thrombosis which can be symptomatic.<sup>54</sup> The final clinical event in the obliteration of brain AVMs following stereotactic radiosurgery can also be progressive venous outflow obstruction and consequent hemorrhage.<sup>55</sup>

Some investigators have treated AVM-associated feeding artery aneurysms with flow-diverting stents<sup>56–58</sup> or stent-assisted coiling.<sup>59</sup> These small case studies have advocated use of a standard dual antiplatelet medication regimen to prevent stent thrombosis. There is insufficient duration of follow-up to assess whether this may lead to a higher risk for intracranial hemorrhage than the baseline risk for AVMs receiving radiosurgery or non-interventional surveillance.

There is literature on the use of antiplatelet or anticoagulants for other indications in patients with incidental, sporadic (ie, not related to a known genetic syndrome) brain AVMs. In the setting of acute neurological symptoms, it can be difficult to differentiate between TIA and AVM-related steal. Because TIA symptoms would warrant antiplatelet medication for stroke prevention, it may be helpful to consider vascular risk factors, the size of the AVM, and history of prior AVM hemorrhage before prescribing chronic antiplatelet medication.<sup>60</sup> In a study of 77 patients with unruptured sporadic brain AVMs who were taking aspirin, the only factor associated with increased risk for AVM rupture over 4 years of surveillance was an AVM nidus size <3.5 cm.<sup>61</sup> Subdural hematoma discovered adjacent to a previously asymptomatic brain AVM in a patient on anticoagulation for atrial fibrillation after a fall may be related to the fall, the AVM, or

both.<sup>62</sup> Chronic antiplatelet or anticoagulant use, however, does not appear to be contraindicated for unruptured AVMs.

Depending on the underlying disease-causing genotype, patients with hereditary hemorrhagic telangiectasia (HHT) have a significantly higher risk for brain AVM—and hence intracerebral hemorrhage—than the general population.<sup>63–64</sup> Presence of multiple brain AVMs is highly predictive of HHT.<sup>65</sup> Two studies of patients with HHT on antithrombotic medications have demonstrated no definite increased risk for spontaneous brain AVM hemorrhage, though both are limited in that not all patients had received neuroimaging to determine if they had underlying brain AVMs, and the specific genotype of each patient was not known.<sup>66–67</sup>

**Recommendation 7: For patients with unruptured brain AVMs there is no indication to change antiplatelet or anticoagulant management instituted for management of another disease (Class IIb, Level C-LD)**

**Intracranial atherosclerotic disease treatment**

The management of ICAD continues to evolve. A disease traditionally treated with medical management alone is increasingly being considered for adjunctive endovascular management with angioplasty and stenting.<sup>68</sup> Medical management of ICAD before 2005 often consisted of anticoagulation using warfarin. However, in 2005, the WASID trial demonstrated that high-dose aspirin was non-inferior to warfarin in regards to the primary outcome of stroke prevention and was associated with significantly fewer adverse events like hemorrhages and death.<sup>69</sup> The results of this trial led to a preferential shift towards the use of antiplatelet agents for the treatment of ICAD lesions. In 2015 the CHANCE trial showed that patients on a DAPT regimen that consisted of aspirin and clopidogrel had fewer thromboembolic events than aspirin alone.<sup>70</sup> Since then, DAPT has become commonly used in ICAD treatment, although additional studies proving its efficacy are needed, especially with newer antiplatelet agents.

**Recommendation 8: Patients with symptomatic ICAD should continue DAPT following neurointerventional treatment for secondary stroke prevention (Class IIa, Level B-NR)**

Despite early data showing higher morbidity and mortality with stenting for ICAD, the need for treatment options in medically refractory ICAD has paved the way for recent trials.<sup>71–74</sup> While new trials potentially allow for variations in current medical practice of antiplatelet regimens in ICAD, most patients treated with balloon angioplasty and/or stenting are still maintained on DAPT before and after the procedure. Intraoperatively, intravenous heparin may be administered to reduce the risk of a thromboembolic event. While angioplasty±stenting may lead to better disease control in the affected vessel, there is no evidence to suggest that neurointervention alters the need for antiplatelet therapy.<sup>75–80</sup>

Data available from non-randomized studies such as the WEAVE trial (Wingspan Stent System Post-Market Surveillance) serve as guidance on post-intervention antiplatelet therapy. This trial was a post-market surveillance registry mandated by the FDA to assess the periprocedural safety of the Wingspan stent system in the treatment of symptomatic ICAD.<sup>80</sup> In this trial, the periprocedural complication rate was comparatively low at 2.6%. The DAPT regimen used was aspirin+P2Y<sub>12</sub> inhibitor for 7–10 days before stenting and for 90 days after stenting, with conversion after 90 days to aspirin alone. This regimen is comparable to those implemented in other intracranial stenting procedures and is deemed an acceptable practice in ICAD.

**Recommendation 9: Following neurointerventional treatment for ICAD, DAPT should be continued for at least 3 months. In the absence of new stroke or TIA symptoms, reversion to SAPT can be considered based on an individual patient's risk of hemorrhage versus ischemia (Class IIb, Level C-LD)**

#### Elective carotid artery stenting

Cervical carotid atherosclerotic plaques contain thrombogenic materials that can cause strokes spontaneously or when the artery is being instrumented for repair. The metallic stents used for carotid artery stenting (CAS) are also thrombogenic, particularly until they are completely covered by native endothelium over weeks to months following placement. CAS can be associated with acute and subacute ischemic complications with an incidence of under 1% (stroke and TIA with modern embolic protection devices and minimal comorbidities) to over 40% (often asymptomatic post-procedure diffusion weighted imaging lesions seen on MRI), as recently reviewed in a study comparing embolic protection devices.<sup>81</sup> Intimal injury of the artery releases procoagulant tissue factors and exposes collagen in the sub-endothelium, thereby triggering platelet activation, thrombus formation, and distal embolization. Although pretreatment with DAPT is often recommended, data are limited regarding the optimal timing, dose, and duration of DAPT treatment for CAS.<sup>82</sup> DAPT consisting of low dose aspirin and clopidogrel has been shown to be more effective than monotherapy in reducing perioperative risks of TIA. When compared with anticoagulation, DAPT has shown fewer ischemic and hemorrhagic complications.<sup>82</sup> In a multi-societal consensus document on carotid stenting and perioperative antiplatelet therapy, it was recommended that the patient should be on DAPT for at least 4 days before the operation.<sup>83</sup> Postoperatively, clopidogrel should be continued for at least 30 days, and aspirin should be continued indefinitely.

For patients with high-grade carotid stenosis undergoing urgent coronary artery bypass grafting (CABG) surgery, CAS can be performed the day before CABG with patients on aspirin and the intravenous glycoprotein IIb/IIIa inhibitor eptifibatide. Eptifibatide can then be discontinued 6 hours before CABG, keeping the patient only on aspirin. When chest tubes have been removed, typically on post-CABG day 2, clopidogrel or another oral antiplatelet agent can be added to aspirin.<sup>84</sup>

**Recommendation 10: Patients undergoing CAS should receive DAPT before and for at least 3 months following their procedure (Class IIa, Level B-R)**

#### Emergency carotid artery stenting during acute stroke treatment

When emergent CAS is needed to treat a tandem stenosis during mechanical thrombectomy, the French ETIS (Endovascular Treatment in Ischemic Stroke) Registry investigators have concluded that an aggressive antiplatelet approach—intraprocedural loading with oral or intravenous glycoprotein IIb/IIIa inhibitors or P2Y12 inhibitors followed by a maintenance intravenous infusion or oral dosing (depending on the agent)—was superior to aspirin alone to prevent subacute stent thrombosis, and was not associated with higher rates of intracranial hemorrhage.<sup>85</sup> Post-procedurally an intravenous regimen was typically converted to an oral regimen, often within 24 hours after the procedure. Other investigators have suggested coadministration of aspirin, and a P2Y12 inhibitor such as clopidogrel; in cases of known clopidogrel resistance, another P2Y12 inhibitor such as ticagrelor may be appropriate.<sup>32</sup>

**Recommendation 11: In patients undergoing CAS during emergent large vessel occlusion ischemic stroke treatment, it may be reasonable to administer a loading dose of intravenous or oral glycoprotein IIb/IIIa or P2Y12 inhibitor followed by maintenance intravenous infusion or oral dosing to prevent stent thrombosis whether or not the patient has received thrombolytic therapy (Class IIb, C-LD).**

#### Cerebral venous thrombosis treatment

Cerebral venous thrombosis (CVT) can involve dural venous sinuses and/or cerebral veins. Due to its propensity to affect young patients, however, no age group is free from this potentially devastating pathology. CVT's diverse forms of presentation and underlying causes can make the initial diagnosis elusive.<sup>86</sup> Anticoagulation has become a mainstay in CVT management.<sup>87</sup> It is important to note, however, that the recommendations regarding anticoagulation for CVT are derived from limited randomized trials and observational data.<sup>86</sup> In a meta-analysis comparing the two major randomized controlled trials comparing anticoagulation with placebo—one using intravenous unfractionated heparin and the other using subcutaneous nadroparin—there was a reduction in death and disability with anticoagulation; however, this was not statistically significant.<sup>88</sup> The literature does not support the use of primary antiplatelet therapy for CVT.

The dilemma of how to manage a patient with CVT and concomitant intracranial hemorrhage arises frequently. Based on randomized trials and observational data, weight adjusted anticoagulation with either unfractionated heparin or weight-based LMWH is recommended.<sup>86</sup> In the special situation of pregnancy, anticoagulation with LMWH is recommended not only during pregnancy, but for at least 6 weeks after pregnancy ends.<sup>86</sup> For children >28 days of age, anticoagulation with LMWH is recommended for at least 3–6 months.<sup>86</sup> Recently, the European Stroke Organization recommended LMWH over OAC as first line therapy, which differs from prior recommendations.<sup>89</sup> There is no clear consensus on the duration of anticoagulation.

Endovascular thrombectomy and thrombolysis in the treatment of CVT, and more specifically cerebral venous sinus thrombosis (CVST), is controversial and often reserved for patients who have had clinical deterioration despite standard medical therapy.<sup>90,91</sup> For an overview of CVT and the role of endovascular therapy, please also see the SNIS Guideline on this topic from 2018.<sup>92</sup> Subsequent to that guideline, the TO-ACT (Thrombolysis or Anticoagulation for Cerebral Venous Thrombosis) trial randomized CVT patients with at least one risk factor for poor clinical outcome to either endovascular therapy (thrombectomy, thrombolysis with alteplase or urokinase, or a combination of thrombectomy plus thrombolysis) plus standard medical management or to standard medical management alone. Death and neurological disability at 1 year post-intervention were not statistically different, and the trial was stopped early for futility after only 67 patients had been enrolled.<sup>93</sup> The increased incidence of CVT and CVST during the COVID-19 pandemic has recently led to increased interest in endovascular treatment for severe cases.<sup>94</sup>

**Recommendation 12: For patients with CVST, anticoagulation with heparin is front-line therapy; endovascular therapy may be considered particularly in cases where clinical deterioration occurs despite medical therapy (Class IIa, Level B-R)**

## CONCLUSIONS

Although the quality of evidence is lower than for coronary interventions due to a lower number of patients and procedures,



neurointerventional antiplatelet and antithrombotic management shares several themes. Prospective and randomized studies are needed to strengthen the data supporting these recommendations.

**Twitter** Fawaz Al-Mufti @almuftifawaz

**Acknowledgements** The authors acknowledge Teri Moore and Eddie Woods for logistical support in the preparation of this document and Megan La Suer for critical review.

**Collaborators** SNIS Standards and Guidelines Committee. SNIS Board of Directors, President J Mocco, MD, President-Elect Mahesh V. Jayaraman, MD, Vice President Johanna T. Fifi, MD, Treasurer Guilherme Dabus, MD, Secretary Reade A. De Leacy, MD, Education Chair Peter Kan, MD, Member-at-Large – Neuroradiology Jeremy J. Heit, MD, PhD, Member-at-Large – Neurosurgery Justin R. Mascitelli, MD, Member-at-Large – Neurology Sunil A. Sheth, MD, Immediate Past President Michael Chen, MD, Second Past President William J. Mack, MD, Audit Committee Chair Justin F. Fraser, MD, Diversity, Equity & Inclusion Chair Jenny Tsai, MD, Governance Committee Chair Michael T. Froehler, MD, PhD, Ex-officio Board Members JNIS Editor-in-Chief Felipe C. Albuquerque, MD, FSNIS Foundation Chair Blaise W. Baxter, MD, FSNIS PSO Medical Director Sameer Ansari, MD, PhD, SNIS Standards Committee Chair Steven Hetts, MD, SNIS Standards and Guidelines Committee Members in 2022: Charles Prestigiacomo, Stavropoula Tjoumakaris, Shivani Pahwa, Kazim Narsinh, Neeraj Chaudhary, Jan-Karl Burkhardt, Franklin Marden.

**Contributors** All named authors had substantial contribution to the conception, design, or analysis or the work presented. All named authors took part in drafting or revising the manuscript critically for intellectual content. All named authors reviewed the final version of the manuscript submitted for publication. All named authors agree to be accountable for the work.

**Funding** This research received no specific grant from any funding agency in the public, commercial, or not-for-profit sectors. It is funded solely from internal resources of the Society of NeuroInterventional Surgery.

**Disclaimer** This guideline update is provided for informational and educational purposes only. Adherence to any recommendations included in this review will not ensure successful treatment in every situation. Furthermore, the recommendations contained in this review should not be interpreted as setting a standard of care, or be deemed inclusive of all proper methods of care nor exclusive of other methods of care reasonably directed to obtaining the same results. The ultimate judgment regarding the propriety of any specific therapy must be made by the physician and the patient in light of all the circumstances presented by the individual patient, and the known variability and biological behavior of the medical condition. This review and its conclusions and recommendations reflect the best available information at the time the review was prepared. The results of future studies may require revisions to the recommendations in this review to reflect new data. The Society of NeuroInterventional Surgery (SNIS) does not warrant the accuracy or completeness of the review and assumes no responsibility for any injury or damage to persons or property arising out of or related to any use of this review or for any errors or omissions.

**Competing interests** None declared.

**Patient consent for publication** Not applicable.

**Ethics approval** Not applicable.

**Provenance and peer review** Not commissioned; externally peer reviewed.

## ORCID iDs

Clemens M Schirmer <http://orcid.org/0000-0003-1743-8781>

Steven W Hetts <http://orcid.org/0000-0001-5885-7259>

## REFERENCES

- Gandhi CD, Bulsara KR, Fifi J, et al. Platelet function inhibitors and platelet function testing in neurointerventional procedures. *J NeuroIntervent Surg* 2014;6:567–77.
- Cuker A, Burnett A, Triller D, et al. Reversal of direct oral anticoagulants: guidance from the anticoagulation forum. *Am J Hematol* 2019;94:697–709.
- Barnes GD, Lucas E, Alexander GC, et al. National trends in ambulatory oral anticoagulant use. *Am J Med* 2015;128:1300–5.
- Badreldin H, Nichols H, Rimsans J, et al. Evaluation of anticoagulation selection for acute venous thromboembolism. *J Thromb Thrombolysis* 2017;43:74–8.
- Kjerpseth LJ, Ellekjær H, Selmer R, et al. Trends in use of warfarin and direct oral anticoagulants in atrial fibrillation in Norway, 2010 to 2015. *Eur J Clin Pharmacol* 2017;73:1417–25.
- Pollack CV Jr, Reilly PA, van Ryn J, et al. Idarucizumab for dabigatran reversal-full cohort analysis. *N Engl J Med* 2017;377:431–41.
- Halvorsen S, Storey RF, Rocca B, et al. Management of antithrombotic therapy after bleeding in patients with coronary artery disease and/or atrial fibrillation: expert consensus paper of the European Society of Cardiology working group on thrombosis. *Eur Heart J* 2017;38:1455–62.
- Sorkin GC, Dumont TM, Wach MM, et al. Carotid artery stenting outcomes: do they correlate with antiplatelet response assays? *J NeuroIntervent Surg* 2014;6:373–8.
- Kass-Hout T, Alderazi YJ, Amuluru K, et al. Neurointerventional stenting and antiplatelet function testing: to do or not to do? *Intervent Neurol* 2014;3:184–9.
- Brinjikji W, Lanzino G, Cloft HJ, et al. Platelet testing is associated with worse clinical outcomes for patients treated with the Pipeline embolization device. *AJNR Am J Neuroradiol* 2015;36:2090–5.
- Hwang G, Huh W, Lee JS, et al. Standard vs modified antiplatelet preparation for preventing thromboembolic events in patients with high on-treatment platelet reactivity undergoing coil embolization for an unruptured intracranial aneurysm: a randomized clinical trial. *JAMA Neurol* 2015;72:764–72.
- Faught RWF, Satti SR, Hurst RW, et al. Heterogeneous practice patterns regarding antiplatelet medications for neuroendovascular stenting in the USA: a multicenter survey. *J NeuroIntervent Surg* 2014;6:774–9.
- Kim KS, Fraser JF, Grupke S, et al. Management of antiplatelet therapy in patients undergoing neuroendovascular procedures. *J Neurosurg* 2018;129:890–905.
- Tonetti DA, Jankowitz BT, Gross BA. Antiplatelet therapy in flow diversion. *Neurosurgery* 2020;86(Suppl 1):S47–52.
- Fiorella D, Thiabolt L, Albuquerque FC, et al. Antiplatelet therapy in neuroendovascular therapeutics. *Neurosurg Clin N Am* 2005;16:517–40.
- Yi X, Wang C, Liu P, et al. Antiplatelet drug resistance is associated with early neurological deterioration in acute minor ischemic stroke in the Chinese population. *J Neurol* 2016;263:1612–9.
- Borchert RJ, Simonato D, R Hickman C, et al. P2Y12 inhibitors for the neurointerventionalist. *Interv Neuroradiol* 2022;28:92–103.
- Brar SS, ten Berg J, Marcucci R, et al. Impact of platelet reactivity on clinical outcomes after percutaneous coronary intervention. A collaborative meta-analysis of individual participant data. *J Am Coll Cardiol* 2011;58:1945–54.
- Chan NC, Eikelboom JW, Ginsberg JS, et al. Role of phenotypic and genetic testing in managing clopidogrel therapy. *Blood* 2014;124:689–99.
- Pereira NL, So D, Bae J-H, et al. International survey of patients undergoing percutaneous coronary intervention and their attitudes toward pharmacogenetic testing. *Pharmacogenet Genomics* 2019;29:76–83.
- Javed K, Unda SR, Holland R, et al. Thromboelastography (TEG) results are predictive of ischemic and hemorrhagic complications in patients with unruptured intracranial aneurysms treated with flow diversion. *Interv Neuroradiol* 2022;28:219–28.
- IgorCS, Mernes R, Lobotesis K, et al. Clopidogrel-related platelet inhibition: correlation with peri-operative adverse events in neurointerventional procedures. *EJNIR* 2014;1437000160.
- Gegri M, Cheves TA, Anderson MN, et al. Discordance in tests used to detect inhibition of the P2Y12 receptor in patients undergoing interventional neuroradiology procedures. *Interv Neuroradiol* 2022;2022:15910199221122858.
- Fifi JT, Brockington C, Narang J, et al. Clopidogrel resistance is associated with thromboembolic complications in patients undergoing neurovascular stenting. *AJNR Am J Neuroradiol* 2013;34:716–20.
- Delgado Almandoz JE, Crandall BM, Scholz JM, et al. Pre-procedure P2Y12 reaction units value predicts perioperative thromboembolic and hemorrhagic complications in patients with cerebral aneurysms treated with the Pipeline embolization device. *J NeuroIntervent Surg* 2013;5(Suppl 3):iii3–10.
- Hanel RA, Kallmes DF, Lopes DK, et al. Prospective study on embolization of intracranial aneurysms with the Pipeline device: the PREMIER study 1 year results. *J NeuroIntervent Surg* 2020;12:62–6.
- Pan Y, Chen W, Xu Y, et al. Genetic polymorphisms and clopidogrel efficacy for acute ischemic stroke or transient ischemic attack: a systematic review and meta-analysis. *Circulation* 2017;135:21–33.
- Wang Y, Meng X, Wang A, et al. Ticagrelor versus clopidogrel in CYP2C19 loss-of-function carriers with stroke or TIA. *N Engl J Med* 2021;385:2520–30.
- Wang Y, Zhao X, Lin J, et al. Association between CYP2C19 loss-of-function allele status and efficacy of clopidogrel for risk reduction among patients with minor stroke or transient ischemic attack. *JAMA* 2016;316:70–8.
- FDA. 2022. Available: <https://www.fda.gov/drugs/drug-safety-and-availability/drug-safety-communications>
- Vandiver JW, Diane Beavers K. Combining oral anticoagulation and antiplatelet therapies: appropriate patient selection. *J Thromb Thrombolysis* 2018;45:423–31.
- Goyal M, Yoshimura S, Milot G, et al. Considerations for antiplatelet management of carotid stenting in the setting of mechanical thrombectomy: a Delphi consensus statement. *AJNR Am J Neuroradiol* 2020;41:2274–9.
- Ryu C-W, Park S, Shin HS, et al. Complications in stent-assisted endovascular therapy of ruptured intracranial aneurysms and relevance to antiplatelet administration: a systematic review. *AJNR Am J Neuroradiol* 2015;36:1682–8.
- Yi HJ, Shin D-S, Kim B-T, et al. Comparison of neuroform Atlas stent-assisted coiling and coiling alone in ruptured intracranial aneurysms: a propensity score matching analysis. *Neurosurgery* 2023;92:607–14.



- 35 Hwang G, Jung C, Park SQ, *et al.* Thromboembolic complications of elective coil embolization of unruptured aneurysms: the effect of oral antiplatelet preparation on periprocedural thromboembolic complication. *Neurosurgery* 2010;67:743–8.
- 36 Delgado Almandoz JE, Kadkhodayan Y, Crandall BM, *et al.* Variability in initial response to standard clopidogrel therapy, delayed conversion to clopidogrel hyper-response, and associated thromboembolic and hemorrhagic complications in patients undergoing endovascular treatment of unruptured cerebral aneurysms. *J NeuroIntervent Surg* 2014;6:767–73.
- 37 Layton KF, Cloft HJ, Gray LA, *et al.* Balloon-assisted coiling of intracranial aneurysms: evaluation of local thrombus formation and symptomatic thromboembolic complications. *AJNR Am J Neuroradiol* 2007;28:1172–5.
- 38 Podlasek A, Al Sultan AA, Assis Z, *et al.* Outcome of intracranial flow diversion according to the antiplatelet regimen used: a systematic review and meta-analysis. *J NeuroIntervent Surg* 2020;12:148–55.
- 39 Stone GW, Witztzenbichler B, Weisz G, *et al.* Platelet reactivity and clinical outcomes after coronary artery implantation of drug-eluting stents (ADAPT-DES): a prospective multicentre registry study. *Lancet* 2013;382:614–23.
- 40 Kearon C, Akl EA. Duration of anticoagulant therapy for deep vein thrombosis and pulmonary embolism. *Blood* 2014;123:1794–801.
- 41 Kearon C, Akl EA, Comerota AJ, *et al.* Antithrombotic therapy for VTE disease: antithrombotic therapy and prevention of thrombosis, 9th ED: American College of Chest Physicians evidence-based clinical practice guidelines. *Chest* 2012;141(2 Suppl):e419S–e496S.
- 42 Kearon C, Akl EA, Ornelas J, *et al.* Antithrombotic therapy for VTE disease: CHEST guideline and expert panel report. *Chest* 2016;149:315–52.
- 43 Lopes RD, Heizer G, Aronson R, *et al.* Antithrombotic therapy after acute coronary syndrome or PCI in atrial fibrillation. *N Engl J Med* 2019;380:1509–24.
- 44 Cannon CP, Bhatt DL, Oldgren J, *et al.* Dual antithrombotic therapy with dabigatran after PCI in atrial fibrillation. *N Engl J Med* 2017;377:1513–24.
- 45 Fiedler KA, Maeng M, Mehili J, *et al.* Duration of triple therapy in patients requiring oral anticoagulation after drug-eluting stent implantation: the ISAR-TRIPLE trial. *J Am Coll Cardiol* 2015;65:1619–29.
- 46 Gibson CM, Mehran R, Bode C, *et al.* Prevention of bleeding in patients with atrial fibrillation undergoing PCI. *N Engl J Med* 2016;375:2423–34.
- 47 Dewilde WJ, Oirbans T, Verheugt FW, *et al.* Use of clopidogrel with or without aspirin in patients taking oral anticoagulant therapy and undergoing percutaneous coronary intervention: an open-label, randomised, controlled trial. *Lancet* 2013;381:1107–15.
- 48 Desai A, Escamilla-Ocasas C, Dilip D, *et al.* Risk of stroke vs. intracerebral hemorrhage in patients with non-valvular atrial fibrillation undergoing percutaneous coronary intervention: a systematic review and meta-analysis of randomized controlled trials comparing dual vs. triple antithrombotic therapy. *J Stroke Cerebrovasc Dis* 2021;30:105654.
- 49 Angiolillo DJ, Bhatt DL, Cannon CP, *et al.* Antithrombotic therapy in patients with atrial fibrillation treated with oral anticoagulation undergoing percutaneous coronary intervention. *Circulation* 2021;143:583–96.
- 50 Richling B, Killer M, Al-Schameri AR, *et al.* Therapy of brain arteriovenous malformations: multimodality treatment from a balanced standpoint. *Neurosurgery* 2006;59(suppl\_5):S3–148.
- 51 Bhanot RD, Kaur J, Sriwastawa S, *et al.* Postoperative “STEMI” in intracerebral hemorrhage due to arteriovenous malformation: a case report and review of literature. *Case Rep Crit Care* 2019;2019:9048239.
- 52 Puccinelli F, Deiva K, Bellesme C, *et al.* Cerebral venous thrombosis after embolization of pediatric AVM with jugular bulb stenosis or occlusion: management and prevention. *Eur J Paediatr Neurol* 2014;18:766–73.
- 53 Morgan MK, Sekhon LHS, Finfer S, *et al.* Delayed neurological deterioration following resection of arteriovenous malformations of the brain. *J Neurosurg* 1999;90:695–701.
- 54 Link MJ, Schermerhorn TC, Fulgham JR, *et al.* Progressive neurological decline after partial spontaneous thrombosis of a Spetzler-Martin grade 5 arteriovenous malformation in a patient with Leiden factor V mutation: management and outcome. *J Neurosurg* 2004;100:940–5.
- 55 Alexander MD, Hetts SW, Young WL, *et al.* Supernova hemorrhage: obliterative hemorrhage of brain arteriovenous malformations following  $\gamma$  knife radiosurgery. *J NeuroIntervent Surg* 2012;4:364–7.
- 56 Kilburg C, Taussky P, Kalani MYS, *et al.* Novel use of flow diversion for the treatment of aneurysms associated with arteriovenous malformations. *Neurosurg Focus* 2017;42:E7.
- 57 Beatty NB, Campos JK, Colby GP, *et al.* Pipeline flex embolization of flow-related aneurysms associated with arteriovenous malformations: a case report. *Intervent Neurol* 2018;7:164–70.
- 58 Phuc DD, Thuan DD, Dai PD, *et al.* Surpass flow-diverter in the treatment of two wide-neck aneurysms in the scheme of an arteriovenous malformation patient: a case study. *Open Access Maced J Med Sci* 2019;7:4316–8.
- 59 Hou K, Xu K, Chen X, *et al.* Endovascular treatment for the flow-related aneurysm originating from an anterior inferior cerebellar artery supplying the cerebellar arteriovenous malformation. *Interv Neurol* 2020;26:566–74.
- 60 Jabbari E, Sethuraman S, Sekaran L. The clinical dilemma of treating transient ischaemic attack-like symptoms in patients with coexisting arteriovenous malformation. *BMJ Case Rep* 2014;2014:bcr2013201315.
- 61 Sturiale CL, Pignotti F, Giordano M, *et al.* Antithrombotic therapy and intracranial bleeding in subjects with sporadic brain arteriovenous malformations: preliminary results from a retrospective study. *Intern Emerg Med* 2018;13:1227–32.
- 62 Parr M, Patel N, Kauffmann J, *et al.* Arteriovenous malformation presenting as traumatic subdural hematoma: a case report. *Surg Neurol Int* 2020;11:203.
- 63 Hetts SW, Shieh JT, Ohliger MA, *et al.* Hereditary hemorrhagic telangiectasia: the convergence of genotype, phenotype, and imaging in modern diagnosis and management of a multisystem disease. *Radiology* 2021;300:17–30.
- 64 Brinjikji W, Iyer VN, Wood CP, *et al.* Prevalence and characteristics of brain arteriovenous malformations in hereditary hemorrhagic telangiectasia: a systematic review and meta-analysis. *J Neurosurg* 2017;127:302–10.
- 65 Bharatha A, Faughnan ME, Kim H, *et al.* Brain arteriovenous malformation multiplicity predicts the diagnosis of hereditary hemorrhagic telangiectasia: quantitative assessment. *Stroke* 2012;43:72–8.
- 66 Edwards CP, Shehata N, Faughnan ME. Hereditary hemorrhagic telangiectasia patients can tolerate anticoagulation. *Ann Hematol* 2012;91:1959–68.
- 67 Devlin HL, Hosman AE, Shovlin CL. Antiplatelet and anticoagulant agents in hereditary hemorrhagic telangiectasia. *N Engl J Med* 2013;368:876–8.
- 68 Tekle WG, Hassan AE. Intracranial atherosclerotic disease: current concepts in medical and surgical management. *Neurology* 2021;97(20 Suppl 2):S145–57.
- 69 Chimowitz MI, Lynn MJ, Howlett-Smith H, *et al.* Comparison of warfarin and aspirin for symptomatic intracranial arterial stenosis. *N Engl J Med* 2005;352:1305–16.
- 70 Liu L, Wong KSL, Leng X, *et al.* Dual antiplatelet therapy in stroke and ICAS: subgroup analysis of chance. *Neurology* 2015;85:1154–62.
- 71 Hussain MS, Fraser JF, Abruzzo T, *et al.* Standard of practice: endovascular treatment of intracranial atherosclerosis. *J NeuroIntervent Surg* 2012;4:397–406.
- 72 Chimowitz MI, Lynn MJ, Derdeyn CP, *et al.* Stenting versus aggressive medical therapy for intracranial arterial stenosis. *N Engl J Med* 2011;365:993–1003.
- 73 Zaidat OO, Fitzsimmons B-F, Woodward BK, *et al.* Effect of a balloon-expandable intracranial stent vs medical therapy on risk of stroke in patients with symptomatic intracranial stenosis. *JAMA* 2015;313:1240.
- 74 Compter A, van der Worp HB, Schonewille WJ, *et al.* VAST: vertebral artery stenting trial. Protocol for a randomised safety and feasibility trial. *Trials* 2008;9:65.
- 75 McTaggart RA, Marks MP. The case for angioplasty in patients with symptomatic intracranial atherosclerosis. *Front Neurol* 2014;5:36.
- 76 Wang Y, Ma Y, Gao P, *et al.* Primary angioplasty without stenting for symptomatic, high-grade intracranial stenosis with poor circulation. *AJNR Am J Neuroradiol* 2018;39:1487–92.
- 77 Qureshi AI, Chaudhry SA, Siddiqi F, *et al.* A randomized trial comparing primary angioplasty versus stent placement for symptomatic intracranial stenosis. *J Vasc Interv Neurol* 2013;6:34–41.
- 78 Fiorella D, Levy EI, Turk AS, *et al.* US multicenter experience with the Wingspan stent system for the treatment of intracranial atheromatous disease. *Stroke* 2007;38:881–7.
- 79 Fiorella DJ, Turk AS, Levy EI. U.S. Wingspan registry: 12-month follow-up results. *Stroke* 2011;42:1976–81.
- 80 Alexander MJ, Zauner A, Chaloupka JC, *et al.* WEAVE trial: final results in 152 on-label patients. *Stroke* 2019;50:889–94.
- 81 Giannopoulos S, Sagris M, Giannopoulos S, *et al.* Embolic protection devices for carotid artery stenting: a network meta-analysis. *Vascular* 2022;2022:17085381221140616.
- 82 McKevitt FM, Randall MS, Cleveland TJ, *et al.* The benefits of combined anti-platelet treatment in carotid artery stenting. *Eur J Vasc Endovasc Surg* 2005;29:522–7.
- 83 Brott TG, Halperin JL, Abbara S, *et al.* 2011 ASA/ACCF/AHA/AANN/AAAS/ACR/ASNR/CNS/SAIP/SCAI/SIR/SNIS/SVM/SVS guideline on the management of patients with extracranial carotid and vertebral artery disease: Executive summary. *J NeuroIntervent Surg* 2011;3:100–30.
- 84 Caton MT, Narsinh KH, Baker A, *et al.* Eptifibatide bridging therapy for staged carotid artery stenting and cardiac surgery: safety and feasibility. *Vascular* 2022;2022:17085381221084813.
- 85 Marnat G, Finistis S, Moreno R, *et al.* Aspirin versus aggressive antiplatelet therapy for acute carotid stenting plus thrombectomy in tandem occlusions: ETIS registry results. *J NeuroIntervent Surg* 2022;jnis-2022-019527.
- 86 Saposnik G, Barinagarrementeria F, Brown RD, *et al.* Diagnosis and management of cerebral venous thrombosis: a statement for healthcare professionals from the American Heart Association/American Stroke Association. *Stroke* 2011;42:1158–92.
- 87 Yaghi S, Shu L, Bakradze E, *et al.* Direct oral anticoagulants versus warfarin in the treatment of cerebral venous thrombosis (ACTION-CVT): a multicenter International study. *Stroke* 2022;53:728–38.
- 88 Coutinho J, de Bruijn SF, Deveber G, *et al.* Anticoagulation for cerebral venous sinus thrombosis. *Cochrane Database Syst Rev* 2011;2011:CD002005.
- 89 Ferro JM, Boussier M-G, Canhão P, *et al.* European Stroke Organization guideline for the diagnosis and treatment of cerebral venous thrombosis-endorsed by the European Academy of Neurology. *Eur J Neurol* 2017;24:1203–13.
- 90 Siddiqui FM, Dandapat S, Banerjee C, *et al.* Mechanical thrombectomy in cerebral venous thrombosis: systematic review of 185 cases. *Stroke* 2015;46:1263–8.
- 91 Ilyas A, Chen C-J, Raper DM, *et al.* Endovascular mechanical thrombectomy for cerebral venous sinus thrombosis: a systematic review. *J NeuroIntervent Surg* 2017;9:1086–92.

- 92 Lee S-K, Mokin M, Hetts SW, *et al.* Current endovascular strategies for cerebral venous thrombosis: report of the SNIS Standards and Guidelines Committee. *J NeuroIntervent Surg* 2018;10:803–10.
- 93 Coutinho JM, Zuurbier SM, Bousser M-G, *et al.* Effect of endovascular treatment with medical management vs standard care on severe cerebral venous thrombosis: the TO-ACT randomized clinical trial. *JAMA Neurol* 2020;77:966–73.
- 94 Longo DL, Ropper AH, Klein JP. Cerebral venous thrombosis. *N Engl J Med* 2021;385:59–64.
- 95 Chen A, Stecker E, A. Warden B. Direct oral anticoagulant use: a practical guide to common clinical challenges. *J Am Heart Assoc* 2020;9:13.
- 96 Steffel J, Verhamme P, Potpara TS, *et al.* The 2018 European Heart Rhythm Association practical guide on the use of non-vitamin K antagonist oral anticoagulants in patients with atrial fibrillation. *Eur Heart J* 2018;39:1330–93.
- 97 Food and Drug Administration. 2011. Available: <https://www.fda.gov/regulatory-information/search-fda-guidance-documents/warnings-and-precautions-contraindications-and-boxed-warning-sections-labeling-human-prescription>
- 98 Ospel JM, Brouwer P, Dorn F, *et al.* Antiplatelet management for stent-assisted coiling and flow diversion of ruptured intracranial aneurysms: a Delphi consensus statement. *AJNR American Journal of Neuroradiology* 2020;41:1856–62.